NCERT Solutions for Class 11 Subjectwise

- Class 11 Mathematics
- Class 11 Physics
- Class 11 Biology
- Class 11 Chemistry
- Class 11 English
- Class 11 Accountancy
- Class 11 Business Study
- Class 11 Economics

#424413

Topic: Eye

Match the terms in column I with those in column II.

Column I	Column II
(a) Compound epithelium	(i) Alimentary canal
(b) Compound eye	(ii) Cockroach
(c) Septal nephridia	(iii) Skin
(d) Open circulatory system	(iv) Mosaic vision
(e) Typhlosole	(v) Earthworm
(f) Osteocytes	(vi) Phallomere
(g) Genitalia	(vii) Bone

Solution

The correct matching pairs are as follows:

Column I	Column II
(a) Compound epithelium	(iii) Skin
(b) Compound eye	(iv) Mosaic vision
(c) Septal nephridia	(v) Earthworm
(d) Open circulatory system	(ii) Cockroach
(e) Typhlosole	(i) Alimentary canal
(f) Osteocytes	(vii) Bone
(g) Genitalia	(vi) Phallomere

#425029

Topic: Eye

Passage

Briefly describe the structure of the following.

(a) Brain

(b) Eye

(c) Ear

Solution

(A) Brain

Brain is the main coordinating centre of the body. It is well protected by the skull. It is externally surrounded by three layers, together known as meninges. The tough outer layer is dura mater, a very thin middle layer is arachnoid and smooth inner layer is called pia mater. The brain is divided into three major parts: forebrain, midbrain and hindbrain.

Forebrain: It consists of cerebrum, thalamus, and hypothalamus. (i) Cerebrum is the largest part of the brain and is divided into two cerebral hemispheres by cerebral fissure. It has four lobes/ functional areas- frontal, lateral, parietal and temporal. (ii) Thalamus is the main centre of coordination for sensory and motor signalling. (iii) Hypothalamus lies at the base of thalamus. It secretes ADH and oxytocin. It is the centre for thirst, hunger, love, affection.

Midbrain: It is located between the thalamus region of the forebrain and pons region of hindbrain. It consists of two parts- optic lobes and cerebral peduncle. It is concerned with the sense of sight and hearing.

Hindbrain: It consists of three regions- cerebellum, pons and medulla oblongata. (i) Cerebellum is the second largest part of the brain. It is responsible for maintaining posture and equilibrium of the body. (ii) Pons is a band of nerve fibre that lies between medulla oblongata and midbrain. It connects the lateral parts of cerebellar hemisphere together. (iii) Medulla oblongata is the posterior part of the brain. It is located beneath the cerebellum and extends to form the spinal cord.

(B) Eye:

The adult human eyeball is spherical in shape. The wall of the eyeball is composed of three layers- sclera, choroid and retina.

Sclera: It is the external layer composed of dense connective tissue. The anterior part of this layer is called cornea.

Choroid: It is the middle layer, bluish in colour and contains many blood vessels. Its posterior two third region is thin while anterior region is thick to form ciliary body. Pigmented and opaque part of ciliary body is known as iris. Anterior part consists of crystalline transparent lens. Aperture surrounded by the iris in front of the lens is pupil.

Retina: It is the inner layer and consists of three sub layers- ganglional cells, bipolar cells and photoreceptor cells. The innermost ganglionic cells give rise to optic nerve fibre that forms optic nerve in each eye and is connected with the brain. Photoreceptor cells are of two types- rods and cones. They contain light sensitive proteins called photo pigments.

(i) Rod cells- Contain the rhodopsin pigment that are highly sensitive to dim light. They are responsible for scotopic vision. (ii) Cone cells- Contain the iodopsin pigment that are highly sensitive to high intensity light. They are responsible for photopic vision.

Optic nerves leave the eye from the median posterior poll of the eye ball. Photoreceptors are absent in this region and hence is called the blind spot. Lateral to the blind spot, a yellowish pigmented spot called macula lutea is present which contains a central pit called fovea. It is the region of greatest visual acuity. The space between the cornea and lens is called aqueous chamber and is filled with aqueous humor. The space between the lens and retina is called vitreous chamber and is filled with vitreous humor.

(C) Ear

Ear is the sense organ for hearing and maintenance of body balance. It consists of three portions – inner ear, middle ear, and outer ear.

Outer ear: It consists of pinna and external auditory meatus. (i) Pinna is a sensitive structure that collects and directs the vibrations into the ear to produce sound. (ii) External auditory meatus is a tubular passage that leads inwards and extends up to the tympanic membrane (eardrum). Tympanic membrane is a thin membrane that lies close to the auditory canal.

Middle ear: It is an air-filled tympanic cavity that is connected with pharynx through eustachian tube. It consists of three ear ossicles called malleus, incus, and stapes that are attached to each other.

Inner ear: The fluid filled inner ear called labyrinth is divided into bony labyrinth and a membranous labyrinth. Bony labyrinth is filled with perilymph while membranous labyrinth is filled with endolymph. Membranous labyrinth is divided into 2 parts. (i) Vestibular apparatus- It is a central sac-like part that is divided into utriculus and sacculus. It also contains three semi-circular canals. (ii) Cochlea- It is a long and coiled outgrowth of sacculus. It is the main hearing organ and consists of three membranes.

#425031

Topic: Eye

Passage

Briefly describe the structure of the following.

Eye

Solution

Eyes are photoreceptors which help in the sensation of vision.

(a) Sclera and cornea form the outer layer.

(i) The sclera is an opaque tissue that is usually known as white of the eye. It is composed of a dense connective tissue.

(ii) The cornea is a transparent anterior portion of the eye that lacks blood vessels and is nourished by lymph from the nearby area. It is slightly bulged forward and helps in focusing light rays with the help of the lens.

(b) Choroid, ciliary body, and iris constitute the middle layer.

(i) Choroid lies next to the sclera and contains numerous blood vessels that provide nutrients and oxygen to the retina and other tissues.

(ii) Ciliary body: The choroid layer is thin over the posterior region and gets thickened in the anterior portion to form the ciliary body. It contains blood vessels, ciliary muscles, and ciliary processes.

(iii) Iris: It regulates the size of muscles by the contraction and relaxation of iris muscle.

The eye contains a transparent, biconvex, and elastic structure just behind the iris. It is known as a lens. The lens is held in position by suspensory ligaments attached to the ciliary body. The lens divides the eye ball into two chambers – an anterior aqueous and posterior vitreous chamber.

(c) The innermost nervous coat of eye contains retina. The retina is the innermost layer. It contains three layers of cells – inner ganglion cells, middle bipolar cells, and outermost photoreceptor cells. The receptor cells present in the retina are of two types – rod cells and cone cells.

(a) Rod cells –The rods contain the rhodopsin pigment (visual purple) that is highly sensitive to dim light. It is responsible for twilight vision.

(b) Cone cells –The cones contain the iodopsin pigment (visual violet) and are highly sensitive to high-intensity light. They are responsible for daylight and colour visions.

The innermost ganglionic cells give rise to optic nerve fibre that forms optic nerve in each eye and is connected to the brain.

#425033

Topic: Ear

Passage

Briefly describe the structure of the following.

Ear

Solution

The ear consists of photoreceptors and statoreceptors. So, it helps in hearing mechanism and balancing of the body.

1. External ear:

It helps in collection of sound waves. It consists of the pinna, external auditory meatus, and a tympanic membrane.

(a) Pinna collects and directs the vibrations into the ear to produce sound.

(b) External auditory meatus is a tubular passage supported by cartilage in the external ear.

(c) The tympanic membrane separates the middle ear from external ear. It helps in the conduction of vibrations to the middle ear.

2. Middle ear:

The middle ear contains a flexible chain of three middle bones called ear ossicles. The three ear ossicles are malleus, incus, and stapes that are attached to each other. It helps to amplify the sound.

3. Internal ear:

It is also known as the labyrinth. Labyrinth is divided into the bony labyrinth and a membranous labyrinth. Bony labyrinth is filled with perilymph while membranous labyrinth is filled with endolymph. Membranous labyrinth is divided into two parts -

(a) Vestibular apparatus:

Vestibular apparatus is a central sac-like part that is divided into utriculus and sacculus. A special group of sensory cells called macula are present in sacculus and utriculus. Vestibular apparatus also contains three semi-circular canals. The lower end of each semi-circular canal contains a projecting ridge called crista ampularis. Each ampulla has a group of sensory cells called crista. Crista and macula are responsible for maintaining the balance of body and posture.

(b) Cochlea :

The cochlea is a long and coiled outgrowth of sacculus. It is the main hearing organ. Cochlea consists of three membranes. The organ of Corti, a hearing organ, is located on the basilar membrane that has hair cells. It conducts the auditory impulse to brain by the auditory nerves.

#425037

Topic: Biochemical aspect of nervous physiology

Distinguish between resting potential and action potential.

Solution

	Resting potential	Action potential
1	It is the potential difference across the nerve fibre when there is no conduction of nerve impulse.	It is the potential difference across nerve fibre when there is conduction of nerve impulse.
2	The membrane is more permeable to K^+ ions than to Na^+ ions.	The membrane is more permeable to Na^+ ions than to K^+ ions
3	The membrane is negatively charged from inside and positively charged from outside. The value of resting potential is -70mV.	The membrane is negatively charged outside and positively charged outside.

#425038

Topic: Eye

Distinguish between choroid and retina.

Solution

	Choroid	Retina
1	Choroid is the middle vascular layer of eye.	Retina is the innermost nervous coat of eye.
2	It contains numerous blood vessels that provide nutrients and oxygen to retina and other tissues.	It contains photoreceptor cells, rods and cones that are associated with twilight and colour vision respectively.
3	It is dark in colour and prevents internal reflection of light in the eye.	The rod cells hep in dark vision and the cone cells helps in the perception of colours.

#425041

Topic: Biochemical aspect of nervous physiology

Explain the following processes:

(a) Polarisation of the membrane of a nerve fibre

(b) Depolarisation of the membrane of a nerve fibre

(c) Conduction of a nerve impulse along a nerve fibre

(d) Transmission of a nerve impulse across a chemical synapse

Solution

During resting condition, the concentration of K+ ions is more inside the axoplasm while the concentration of Na+ ions is more outside the axoplasm. As a result, the potassium ions move faster from inside to outside as compared to sodium ions. Therefore, the membrane becomes positively charged outside and negatively charged inside. This is known as the polarization of membrane or polarized nerve.

When an electrical stimulus is received by a nerve fibre, an action potential is generated. The membrane becomes permeable to sodium ions than to potassium ions. This results in a positive charge inside and negative charge outside the nerve fibre. Hence, the membrane is said to be depolarised. The potential generated at this phase is known as the action potential. As the action potential reaches its maximum value, the membrane potential gets reversed and this state is known as repolarization.

Synapse is a small gap that occurs between the last portion of the axon of one neuron and the dendrite of next neuron. When an impulse reaches at the end plate of the axon, vesicles consisting of a chemical substance or neurotransmitter, such as acetylcholine, fuse with the plasma membrane. This chemical moves across the cleft and attaches to chemo-receptors present on the membrane of the dendrite of next neuron. This binding of chemical with chemo-receptors leads to the depolarization of membrane and generates a nerve impulse across nerve fibre.

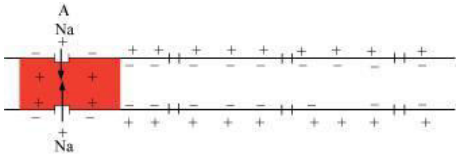

#425043

Topic: Biochemical aspect of nervous physiology

Explain the process of depolarisation of the membrane of a nerve fibre.

Solution

The nerve fibre is at resting phase when it is not stimulated by any impulse. They possess a potential difference along the membrane which is known as resting potential (-70mv). The membrane is negatively charged inside due to the lower concentration of potassium ions and positively charged outside due to the high concentration of sodium ions.

When an electrical stimulus is received by a nerve fibre, an action potential is generated. The membrane becomes permeable to sodium ions than to potassium ions. This results in a positive charge inside and negative charge outside the nerve fibre. Hence, the membrane is said to be depolarised.

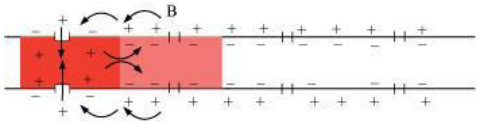

#425045

Topic: Biochemical aspect of nervous physiology

Explain the process of conduction of a nerve impulse along a nerve fibre.

Solution

The nerve fibre is at resting phase when it is not stimulated by any impulse. They possess a potential difference along the membrane which is known as resting potential (-70mv). The membrane is negatively charged inside due to the lower concentration of potassium ions and positively charged outside due to the high concentration of sodium ions.

When an electrical stimulus is received by a nerve fibre, an action potential is generated. The membrane becomes permeable to sodium ions than to potassium ions. This results in a positive charge inside and negative charge outside the nerve fibre. Hence, the membrane is said to be depolarised.

The potential generated at this phase is known as the action potential. As the action potential reaches its maximum value, the membrane potential gets reversed and this state is known as repolarization. By sequential activity of the nerve conduction, it reaches the terminal end of the axon and stimulates the synaptic vesicles which release the neurotransmitters. The neurotransmitters cross the synaptic membrane and reach the dendrite of the next neuron.

#425048

Topic: Biochemical aspect of nervous physiology

Explain the transmission of a nerve impulse across a chemical synapse.

Solution

Synapse is a small gap that occurs between the last portion of the axon of one neuron and the dendrite of next neuron. When an impulse reaches at the end plate of the axon, vesicles consisting of a chemical substance or neurotransmitter, such as acetylcholine, fuse with the plasma membrane. This chemical moves across the cleft and attaches to chemo-receptors present on the membrane of the dendrite of next neuron. This binding of chemical with chemo-receptors leads to the depolarization of membrane and generates a nerve impulse across nerve fibre. The chemical, acetylcholine, is inactivated by enzyme acetylcholinesterase. The enzyme is present in the postsynaptic membrane of the dendrite.

It hydrolyses acetylcholine and this allows the membrane to repolarize.

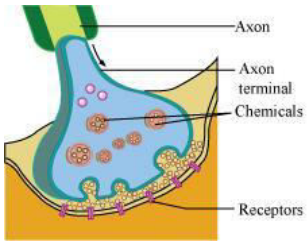

#425050

Topic: Eye

Draw labelled diagrams of the following:

(a) Neuron

(b) Brain

(c) Eye

(d) Ear

Solution

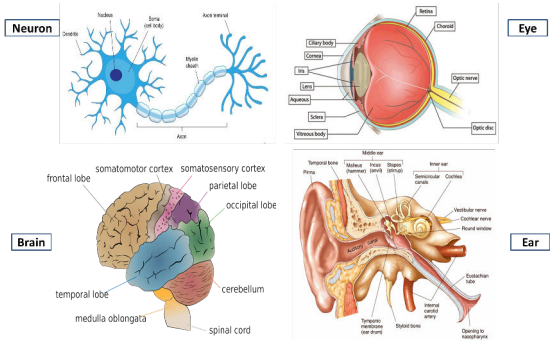

#425052

Topic: Components of nervous system

Draw a labelled diagram of brain.

Solution

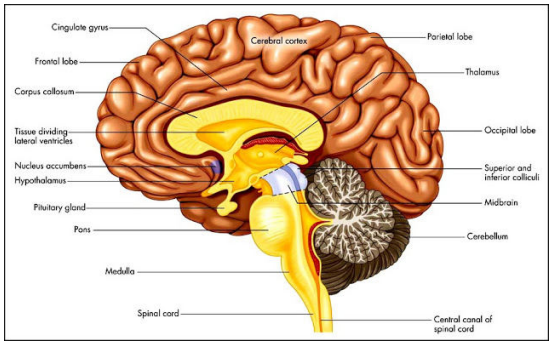

#425054

Topic: Eye

Draw a well labelled diagram of eye.

Solution

The adult human eyeball is spherical in shape. The wall of the eyeball is composed of three layers- sclera, choroid and retina.

Sclera: It is the external layer composed of dense connective tissue. The anterior part of this layer is called cornea.

Choroid: It is the middle layer, bluish in colour and contains many blood vessels. Its posterior two third region is thin while anterior region is thick to form ciliary body. Pigmented and opaque part of ciliary body is known as iris. Anterior part consists of crystalline transparent lens. Aperture surrounded by the iris in front of the lens is pupil.

Retina: It is the inner layer and consists of three sub layers- ganglional cells, bipolar cells and photoreceptor cells. The innermost ganglionic cells give rise to optic nerve fibre that forms optic nerve in each eye and is connected with the brain. Photoreceptor cells are of two types- rods and cones. They contain light sensitive proteins called photo pigments. (i) Rod cells- Contain the rhodopsin pigment that are highly sensitive to dim light. They are responsible for scotopic vision. (ii) Cone cells- Contain the iodopsin pigment that are highly sensitive to high intensity light. They are responsible for photopic vision.

Optic nerves leave the eye from the median posterior poll of the eye ball. Photoreceptors are absent in this region and hence is called the blind spot. Lateral to the blind spot, a yellowish pigmented spot called macula lutea is present which contains a central pit called fovea. It is the region of greatest visual acuity. The space between the cornea and lens is called aqueous chamber and is filled with aqueous humor. The space between the lens and retina is called vitreous chamber and is filled with vitreous humor.

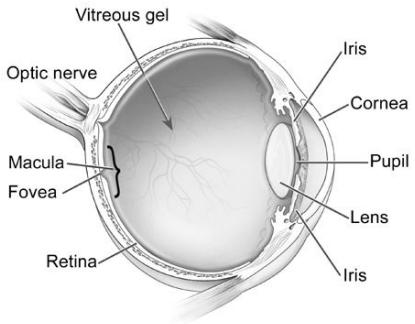

#425055

Topic: Ear

Draw a well-labelled diagram of an ear.

Solution

Ear:

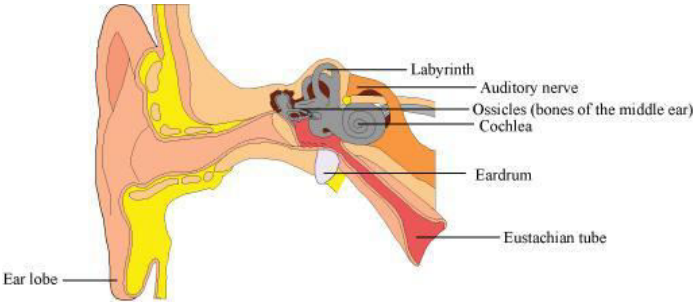

#425057

Topic: Biochemical aspect of nervous physiology

Write short notes on the following:

(a) Neural coordination

(b) Forebrain

(c) Midbrain

(d) Hindbrain

(e) Retina

(f) Ear ossicles

(g) Cochlea

(h) Organ of Corti

(i) Synapse

Solution

(a) Neural coordination: The nervous system provides quick coordination of various parts of the body through electric impulses. These impulses are short lived but quick.

(b) Forebrain consists of the cerebrum, cerebral hemispheres, olfactory lobes and diencephalon (thalamus and hypothalamus). It helps in the interpretation of stimulus received by effector organs.

(c) Midbrain consists of tectum (visual and auditory stimuli) and tegmentum (contains nuclei for pain modulation, motor coordination and movement planning). It helps in the relay of impulse from effector organ to the forebrain.

(d) Pons, cerebellum and medulla together form the hindbrain. It helps to maintain the balance of body and body posture. It also has regulatory centres for controlling the involuntary actions.

(e) The retina is the innermost layer of the eyeball and contains photoreceptor rods and cones.

(f) Ear ossicles: Three small bones present between the tympanic membrane and oval window are collectively referred to as ossicles, they are namely malleus, incus and stapes. It increases the amplification of sound waves.

(g) Cochlea: Cochlea is a spiral hollow structure containing three fluid-filled canals. Organ of corti is located in middle cochlear canal and has hair cells (mechanoreceptors) on its basilar membrane. Thus, cochlea houses sensory system for hearing only and is not associated with balancing.

(h) Organ of corti: Organ of corti is located in middle cochlear canal and has hair cells (mechanoreceptors) on its basilar membrane. It generates the auditory impulse which is carried by auditory nerves.

(i) Synapse: Two neurons are never physically connected to each other and synapse is the region of close proximity between two neurons where information from one neuron is transmitted to the next one.

#425060

Topic: Components of nervous system

Write short note on forebrain.

Solution

The brain is divided into three major parts known as forebrain, midbrain and hindbrain.

(i) Cerebrum:

The cerebrum is the largest part of the brain. It is divided into two cerebral hemispheres joined by the corpus callosum. The cerebral hemispheres are covered by a layer of cells known as cerebral cortex or grey matter. The innermost part of cerebrum gives an opaque white appearance to the layer and is known as the white matter. It helps to interpret the received stimulus from the effector organ.

(ii) Thalamus:

The thalamus is the main centre of coordination for sensory and motor signalling. It is wrapped by cerebrum.

(iii) Hypothalamus:

It lies at the base of the thalamus and contains a number of centres that regulate body temperature and the urge for eating and drinking. Some regions of the cerebrum, along with hypothalamus, are involved in the regulation of sexual behaviour and expression of emotional reactions such as excitement, pleasure, fear, etc.

#425061

Topic: Components of nervous system

Write a short note on midbrain.

Solution

Midbrain is located between the thalamus region of the forebrain and pons region of the hindbrain. It helps in the relay of information from the hindbrain to the midbrain. The dorsal surface of midbrain consists of superior and inferior corpora bigemina and four round lobes called corpora quadrigemina. A canal known as cerebral aqueduct passes through the midbrain. The midbrain is concerned with the sense of sight and hearing.

#425063

Topic: Components of nervous system

Write short note on hindbrain.

Solution

Hindbrain consists of three regions pons, cerebellum, and medulla oblongata.

(i) Pons is a band of nerve fibres that lies between the medulla oblongata and midbrain. It helps to regulate several involuntary processes like respiration etc.

(ii) The cerebellum is a large and well-developed part of the hindbrain. It regulates motor movement which maintains posture, balance, coordination and speech.

(iii) The medulla oblongata is the posterior and simplest part of the brain. It is located beneath the cerebellum. Its lower end extends in the form of the spinal cord and leaves the skull through the foramen magnum.

#425065

Topic: Eye

Write short note on retina.

Solution

Retina is the innermost layer. It contains three layers of cells viz., inner ganglion cells, middle bipolar cells, and outermost photoreceptor cells. The receptor cells present in the retina are of two types, rod cells and cone cells.

(i) Rod cells: The rods contain rhodopsin pigment (visual purple), which is highly sensitive to dim light. It is responsible for twilight vision.

(ii) Cone cells: The cones contain iodopsin pigment (visual violet) and are highly sensitive to high-intensity light. They are responsible for daylight and colour visions.

The innermost ganglionic cells give rise to optic nerve fibre that forms optic nerve in each eye and is connected to the brain. In this region, the photoreceptor cells are absent. Hence, it is known as the blind spot. At the posterior part, lateral to the blind spot, there is a pigmented spot called macula lutea. This spot has a shallow depression at its middle known as the fovea. Fovea has only cone cells. They are devoid of rod cells. Hence, it is the place of most distinct vision.

#425066

Topic: Ear

Write short note on ear ossicles.

Solution

The middle ear contains a flexible chain of three middle bones called as ear ossicles. The three ear ossicles are malleus, incus and stapes. The malleus is attached to tympanic membrane on one side and to incus on the other side. The incus is connected with stapes. Stapes, in turn, are attached to an oval membrane, fenestra ovalis, of the internal ear. The ear ossicles act as a lever that transmits sound waves from external ear to internal ear.

#425068

Topic: Ear

Write short note on cochlea.

Solution

The cochlea is a long, coiled outgrowth of sacculus. It is the main hearing organ. The cochlea forms three chambers:

(i) Upper − scala vestibule

(ii) Middle − scala media

(iii) Lower − scale tympani

The floor of the scala media is basilar membrane while its roof is Reissner's membrane. Reissner's membrane gives out a projection called as the tectorial membrane. The organ of Corti, a hearing organ, is located on the basilar membrane. Organ of Corti contains receptor hair cells. The upper scala vestibule and lower scala tympani contain perilymph.

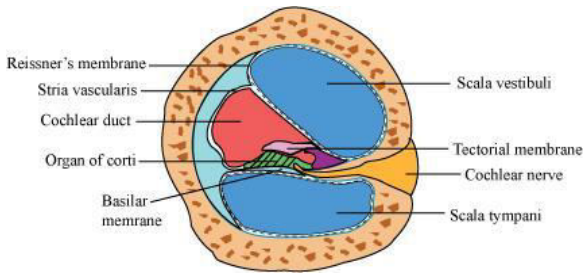

#425069

Topic: Ear

Write short note on organ of corti.

Solution

Organ of Corti is the hearing organ. It is located on the basilar membrane that contains hair cells. Hair cells act as auditory receptors. They are present on the internal side of the organ of Corti on the basilar membrane and lined by an elastic tectorial membrane. As the vibrations approaches the hair vibrates and come in contact with the tectorial membrane which generates an auditory impulse. This impulse is carried to the brain by audtory nerve.

#425070

Topic: Biochemical aspect of nervous physiology

Write short note on synapse.

Solution

Synapse is a junction between the axon terminal of one neuron and the dendrite of next neuron. It is separated by a small gap known as synaptic cleft. There are two types of synapses:

(a) Electrical synapse

(b) Chemical synapse

In electrical synapses, the pre and post synaptic neurons lie in close proximity to each other. Hence, the impulse can move directly from one neuron to another across the synapse. This represents a faster method of impulse transmission.

In chemical synapses, the pre and post-synaptic neurons are not in close proximity. They are separated by a synaptic cleft. The transmission of nerve impulses is carried out by chemicals such as neurotransmitters.

#425072

Topic: Biochemical aspect of nervous physiology

Give a brief account on:

(a) Mechanism of synaptic transmission

(b) Mechanism of vision

(c) Mechanism of hearing

Solution

(a) Synapse is a junction between two neurons. It is present between the axon terminal of one neuron and the dendrite of next neuron separated by a cleft.

There are two ways of synaptic transmission.

(1) Chemical transmission

(2) Electrical transmission

1. Chemical transmission: When a nerve impulse reaches the end plate of the axon, it releases a neurotransmitter (acetylcholine) across the synaptic cleft. This chemical is synthesized in the cell body of the neuron and is transported to the axon terminal. The acetylcholine diffuses across the cleft and binds to the receptors present on the membrane of next neuron. This causes depolarization of membrane and initiates an action potential.

2. Electrical transmission: In this type of transmission, an electric current is formed in the neuron. This electric current generates an action potential and leads to transmission of a nerve impulse across the nerve fibre. This represents a faster method of nerve conduction than the chemical method of transmission.

(b) Mechanism of vision

Retina is the innermost layer of the eye. It contains three layers of cells – inner ganglion cells, middle bipolar cells, and outermost photoreceptor cells. A photoreceptor cell is composed of a protein called as opsin and an aldehyde of vitamin A called as retinal. When light rays are focused on the retina through the cornea, it leads to the dissociation of retinal from opsin protein. This changes the structure of opsin. As the structure of opsin changes, the permeability of membrane changes, generating a potential difference in the cells. This generates an action potential in the ganglionic cells and is transmitted to the visual cortex of the brain via optic nerves. In the cortex region of the brain, the impulses are analysed and the image is formed on the retina.

(c) Mechanism of hearing

The pinna of the external region collects the sound waves and directs it towards ear drum or external auditory canal. These waves strike the tympanic membrane and vibrations are created. Then, these vibrations are transmitted to the oval window, fenestra ovalis, through three ear ossicles, named as malleus, incus, and stapes. These ear ossicles act as a lever and transmit the sound waves to internal ear. These vibrations from fenestra ovalis are transmitted into the cochlear fluid. This generates sound waves in the lymph. The formation of waves generates a ripple in the basilar membrane. This movement bends the sensory hair cells present on the organ of Corti against tectorial membrane. As a result of this, sound waves are converted into nerve impulses. These impulses are then carried to the auditory cortex of brain via auditory nerves. In cerebral cortex of the brain, the impulses are analysed and the sound is recognized.

#425073

Topic: Eye

Give a brief account on mechanism of vision.

Solution

The retina is the innermost layer of the eye. It helps in the sensation of vision. It is a three-layered membrane which consists of inner ganglion cells, middle bipolar cells, and outermost photoreceptor cells. A photoreceptor cell is composed of a protein called as opsin and an aldehyde of vitamin A called as retinal. When light rays are focused on the retina through the cornea, it leads to the dissociation of retinal from opsin protein. This changes the structure of opsin. As the structure of opsin changes, the permeability of membrane changes, generating a potential difference in the cells. This generates an action potential in the ganglionic cells and is transmitted to the visual cortex of the brain via optic nerves. In the cortex region of the brain, the impulses are analysed and the image is formed on the retina.

#425074

Topic: Ear

Give account on mechanism of hearing.

Solution

The pinna of the external region collects the sound waves and directs it towards ear drum or external auditory canal. These waves strike the tympanic membrane and vibrations are created. Then, these vibrations are transmitted to the oval window, fenestra ovalis, through three ear ossicles, named as malleus, incus, and stapes. These ear ossicles act as a lever and transmit the sound waves to internal ear. These vibrations from fenestra ovalis are transmitted into the cochlear fluid. This generates sound waves in the lymph. The formation of waves generates a ripple in the basilar membrane. This movement bends the sensory hair cells present on the organ of Corti against tectorial membrane. As a result of this, sound waves are converted into nerve impulses. These impulses are then carried to the auditory cortex of brain via auditory nerves. In cerebral cortex of the brain, the impulses are analysed and the sound is recognized.

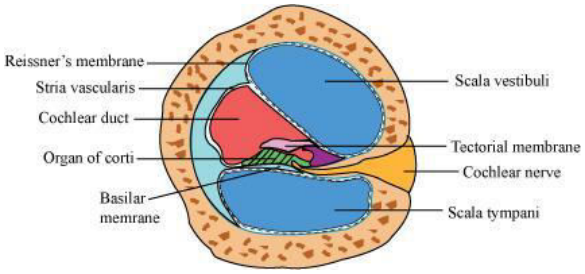

#425076
Topic: Eye

Passage

Answer briefly:

(a) How do you perceive the colour of an object?
(b) Which part of our body helps us in maintaining the body balance?
(c) How does the eye regulate the amount of light that falls on the retina?

Solution

a) Photoreceptors are cells that are sensitive to light. They are of two types – rods and cones. These are present in the retina. Cones help in distinguishing colours. There are three types of cone cells – those responding to green light, those responding to blue light, and those responding to red light. These cells are stimulated by different lights, from different sources. The combinations of the signals generated help us see the different colours.
b) The inner ear is part of an ear is responsible for maintaining the body balance. The vestibular apparatus and the semicircular canal is responsible for maintaining the balance of the body.
c) A pupil is like an aperture in an eye. It dilates in low light and constricts in intense light when the light falls on the retina.

#425077
Topic: Ear

Passage

Answer briefly:

Which part of our body helps us in maintaining the body balance?

Solution

Vestibular apparatus is located in the internal ear, above the cochlea and helps in maintaining body balance. Crista and macula are the sensory spots of the vestibular apparatus controlling dynamic equilibrium.

#425078
Topic: Eye

Passage

Answer briefly:

How does the eye regulate the amount of light that falls on the retina?

Solution

The eye is a sense organ used for the purpose of vision. Rods and cones are two types of photoreceptors present in the retina of the eye. The size of the pupil regulates the amount of light entering the eye. In presence of bright light the pupil contracts to limit the amount of light entering the eyes. In presence of dim light, the pupils dilate to increase the amount of light entering the eyes.

#425080

Topic: Biochemical aspect of nervous physiology

Passage

Explain the following:

(a) Role of Na+ in the generation of action potential.

(b) Mechanism of generation of light-induced impulse in the retina.

(c) The mechanism through which a sound produces a nerve impulse in the inner ear.

Solution

Sodium ions play an important role in the generation of action potential. When a nerve fibre is stimulated, the membrane potential decreases. The membrane becomes more permeable to Na+ ions than to K+ ions. As a result, Na+ diffuses from the outside to the inside of the membrane. This causes the inside of the membrane to become positively charged, while the outer membrane gains a negative charge. This reversal of polarity across the membrane is known as depolarization. The rapid inflow of Na+ ions causes the membrane potential to increase, thereby generating an action potential.

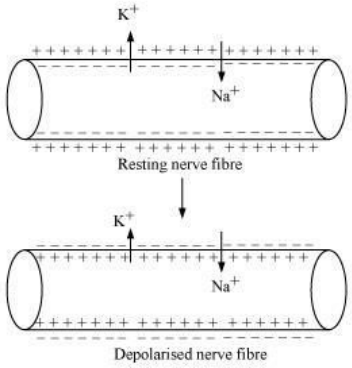

b) In the eye retina have photopigments like retinal and opsin. Light dissociates the retinal from opsin which changes the structure of opsin and generates action potential.
c) When sound falls over the ear drum, it is then transmitted to the inner ear by ear ossicles. The vibrations are passed through the oval window onto the fluid of the cochlea, where they generate waves in the lymph. These waves induces the hair cell. As a result nerve impulses are generated in the associated afferent neurons and transmitted to auditory cortex of brain via auditory nerves.

#425081

Topic: Eye

Passage

Explain the following:

Mechanism of generation of light-induced impulse in the retina.

Solution

Retina is the photoreceptive layer of the eye and it helps in sensation of vision. It has two type of cell rod cell and cone cell. Photoreceptor cells are composed of a protein called opsin and an aldehyde of vitamin A called retinal. When light rays are focused on the retina through the cornea, retinal gets dissociated from opsin. As a result, the structure of opsin gets changed. This, in turn, causes the permeability of the membrane to change, thereby generating a potential difference in the cells. Consequently, an action potential is generated in the ganglion cells and is transmitted to the visual cortex of the brain via the optic nerves. In the cortex region of the brain, the impulses are analysed and the image is formed on the retina.

#425082

Topic: Ear

Passage

Explain the following:

Mechanism through which a sound produces a nerve impulse in the inner ear.

Solution

The external ear collects the sound waves through the pinna. The sound waves enters the external auditory canal and vibrates the tympanic membrane. The ear drum then vibrates the sound waves and conducts the sound waves to the middle ear where the ear ossicles increases the intensity of the sound waves. These vibrating sound waves are conducted through the oval window to the fluid in the cochlea. Consequently, a movement is created in the lymph. This movement produces vibrations in the basilar membrane, which in turn stimulate the auditory hair cells. These cells generate a nerve impulse, conducting it to the auditory cortex of the brain via afferent fibres. The auditory cortex region interprets the nerve impulse and sound is recognised.

#425084

Topic: Components of nervous system

Differentiate between:

(a) Myelinated and non-myelinated axons

(b) Dendrites and axons

(c) Rods and cones

(d) Thalamus and hypothalamus

(e) Cerebrum and cerebellum

Solution

(a) A myelinated neuron is a neuron whose axon is covered by the myelin sheath (myelin means white). The conduction of nerve impulse is faster in this neuron than non-myelinated neuron due to the presence of myelin sheath over the axon. Myelin sheath avoids the loss of impulse during conduction.

Whereas non-myelinated neuron is the neuron whose axon is not covered by the myelin sheath. The conduction of nerve impulse in this neuron is slow than myelinated neuron due to the absence of myelin sheath. There are more chances of loss of impulse during conduction.

(b) Axon is a single long, thick neurite structure in the neuron. It contains neurofibrils. It is the efferent component of the impulse. Whereas dendrites are multiple short and thick neurites in the neuron. It is the branched structure which contains both neurofibrils and Nissl's granules. It is the afferent components of the neurons.

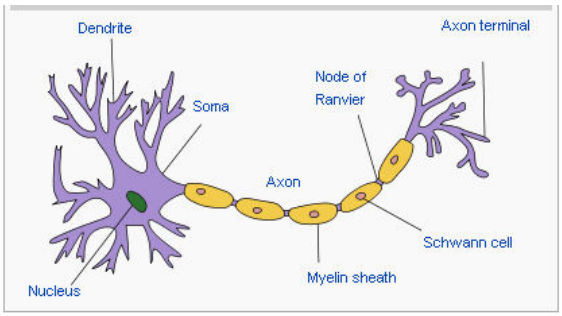

(c) Rods are the photoreceptor cells of the retina that are sensitive to dim light. They have the visual purple pigment called as rhodopsin.

Whereas cones are the photoreceptor cells of the retina that are sensitive to bright light. They have the visual violet pigment called as iodopsin.

(d) Thalamus and hypothalamus are both names of structures in the brain. While the hypothalamus is cone-shaped, the thalamus consists of two connected lobes, one located in each hemisphere. The hypothalamus regulates the body's vital metabolic processes, affecting temperature, blood pressure, hunger, thirst and sleep. It controls the endocrine system by affecting the pituitary gland's production of hormones. The thalamus takes information from a number of different areas of the brain and relays it to the cerebral cortex, the outer layer of gray matter where higher level brain functions take place.

(e) The cerebrum is the part of the forebrain that controls voluntary functions. It is the place where intelligence, will power, memory, etc., reside. It is the largest part of the brain, forming four fifths of its weight. Whereas cerebellum is the part of the hindbrain that controls voluntary functions and controls the equilibrium. It is the second largest part of the brain, forming one eight of its mass.

#425085

Topic: Components of nervous system

Differentiate between dendrites and axon.

Solution

Axon	Dendrites
It is single and very long (several metres) and of uniform diameter	They are short (under 1.5mm), heavily branched and tapering
Carries nerve impulse away from the cell body to the next neuron	Carries nerve impulses from synapses towards the cell body
Single per neuron	Usually many per neuron
Transmits neuron signals	Receives neuron signals
May be myelinated or non- myelinated	Always non- myelinated
Nissl's granules absent	Nissl's granules present

#425086

Topic: Eye

Differentiate between rods and cones.

Solution

	Rods	Cones
1	Rods help in twilight vision.	Cones help in colour vision.
2	They have visual purple pigment called as rhodopsin.	They have visual violet pigment called as iodopsin.
3	Rods are the photoreceptor cells of the retina that are sensitive to dim light.	Cones are the photoreceptor cells of the retina that are sensitive to bright light.

#425087

Topic: Components of nervous system

Distinguish between thalamus and hypothalamus.

Solution

Thalamus	Hypothalamus
Thalamus is the part of diencephalon of the forebrain.	Hypothalamus is a mass of grey matter present at the base of the cerebrum.
It is associated with recognition of pain, temperature and hard touch.	It secretes releasing and inhibition factor which regulates the hormonal secretion of the pituitary gland.

#425090

Topic: Components of nervous system

Distinguish between cerebrum and cerebellum.

Solution

Cerebrum	Cerebellum
The cerebrum is the part of the forebrain.	Cerebellum is part of the hindbrain.
Cerebrum serves to receive sensory inputs, to bring about integration before commanding voluntary motor responses, to coordinate the activities of another part of the brain, and to carry out higher thought processes for learning, memory, language and speech.	Cerebellum serves to coordinate the voluntary movements of skeletal muscles as well as posture, balance and equilibrium.

#425092

Topic: Ear

Answer the following:

(a) Which part of the ear determines the pitch of a sound?

(b) Which part of the human brain is the most developed?

(c) Which part of our central neural system acts as a master clock?

Solution

(a) Cochlea determines the pitch of a sound.

(b) Forebrain is largest and the most developed part of the human brain.

(c) Hypothalamus acts as a master clock in the human body.

#425093

Topic: Components of nervous system

Which part of the human brain is the most developed?

Solution

The forebrain is the largest part of the human brain. It is divided into two parts the right cerebrum and the left cerebrum. The two cerebral hemisphere is joined by the corpus callosum. It has sensory areas like frontal lobe, parietal lobe, temporal lobe, occipital lobe, olfactory lobe. These areas are specific for the interpretation of stimulus received by the effector organs. Thus, it is considered as most developed part of the brain.

#425094

Topic: Components of nervous system

Which part of our central neural system acts as a master clock?

Solution

Hypothalamus acts as a master clock in the human body. The master circadian clock that regulates 24-hour cycles throughout our bodies is found in a region called the suprachiasmatic nuclei (SCN) in the hypothalamus of the brain. The SCN is made up of two tiny clusters of several thousand nerve cells that "tell time" based on external cues, such as light and darkness. The SCN regulates sleep, metabolism, and hormone production.

#425095

Topic: Eye

The region of the vertebrate eye, where the optic nerve passes out of the retina, is called as

(a) Fovea

(b) Iris

(c) Blind spot

(d) Optic chaisma

Solution

The region of the vertebrate eye, where the optic nerve passes out of the retina, is called as the blind spot. The blind spot is the part where the optic nerve passes out of the retina. Photoreceptors are absent from this region. the optic nerve is the nerve which carries the impulse from the photoreceptors to the optic lobes of the brain.

Optic chaisma is the place where the optic lobes overlap.

Iris is the part of the eye which regulates the size of the eye and controls the amount of light.

The fovea is the is the point where there are a maximum number of cone cells.

#425097

Topic: Components of nervous system

Distinguish between:

(a) Afferent neurons and efferent neurons

(b) Impulse conduction in a myelinated nerve fibre and unmyelinated nerve fibre

(c) Aqueous humor and vitreous humor

(d) Blind spot and yellow spot

(e) Cranial nerves and spinal nerves

Solution

(a) Afferent neuron conducts nerve impulses toward the brain or the spinal cord and are also called as sensory neurons. While efferent neuron conducts nerve impulses from the brain or spinal cord to the effector organs such as muscles or glands and are also called as motor neurons.

(b) In a myelinated nerve fibre, the action potential is conducted from one node to another and the conduction of impulses is faster. whereas in an unmyelinated nerve fibre, the action potential is not conducted from node to node. It is carried along the whole length of the nerve fibre and the conduction of impulses is slower.

(c) Aqueous humor is a clear liquid found between the cornea and the lens of eye, whereas vitreous humor is a clear gelatinous mass found in the rear part of the eyeball between the lens and retina. Aqueous humor is continuously generated and continuously drains from the front of the eye throughout the lifetime, whereas vitreous humor is produced only during the embryonic stage and stays for the entire lifetime. Vitreous humor does not replenish while aqueous humor does. The volume of vitreous humor is higher than that of aqueous humor in a single eye.

(d) Blind spot is a spot on the retina present at the point of origin of the optic nerve and are insensitive to light as both rods and cones are absent.

Whereas yellow spot is a small area on the retina present at the posterior pole of the eye, lateral to the blind spot and is sensitive to bright light as cones are present.

(e)There are 12 pairs of cranial nerves arises from the brain. While spinal nerves arise from the spinal cord and tThere are 31 pairs of spinal nerves.

#425098

Topic: Components of nervous system

Give the difference between impulse conduction in a myelinated nerve fibre and unmyelinated nerve fibre.

Solution

Impulse conduction in a myelinated nerve fibre -

1. In a myelinated nerve fibre, the action potential is conducted from one node to another.

2. The conduction of impulses is faster.

Impulse conduction in an unmyelinated nerve fibre -

1. In an unmyelinated nerve fibre, the action potential is not conducted from node to node. It is carried along the whole length of the nerve fibre.

2. The conduction of impulses is slower.

#425099

Topic: Eye

Give the difference between aqueous humor and vitreous humor.

Solution

1. Aqueous humor is a clear liquid found between the cornea and the lens of eye, whereas vitreous humor is a clear gelatinous mass found in the rear part of the eyeball between the lens and retina.

2. Aqueous humor is continuously generated and continuously drains from the front of the eye throughout the lifetime, whereas vitreous humor is produced only during the embryonic stage and stays for the entire lifetime.

3. Vitreous humor does not replenish while aqueous humor does.

4. The volume of vitreous humor is higher than that of aqueous humor in a single eye.

#425100

Topic: Eye

Give difference between blind spot and yellow spot.

Solution

	Blind spot	Yellow spot
1	Blind spot is a spot on the retina present at the point of origin of the optic nerve.	Yellow spot is a small area on the retina present at the posterior pole of the eye, lateral to the blind spot.
2	Photoreceptor cells are absent from this region.	Only cones are present in this region.
3	They are insensitive to light as both rods and cones are absent.	They are sensitive to bright light as cones are present.

#464820

Topic: Reflex

How are involuntary actions and reflex actions different from each other?

Solution

The involuntary actions include the skeletal muscle movement those are under regulation of the autonomic division (ANS) of the peripheral nervous system which consists of motor fibres that relay nerve impulses from CNS (Central Nervous System) to cardiac and smooth muscles and glands, thereby controls the functioning of internal organs, without our conscious control. Reflex action is an automatic, quick and innate response to particular stimuli that is mediated by a reflex arc. A simple reflex arc consists of sensory receptors, afferent neuron, spinal cord, efferent neuron and effector organ. Therefore, involuntary actions are unconscious responses produced by brain while reflex actions do not involve the brain for information processing.